

CASE REPORT

Leg cramps in pregnancy caused by chronic compartment syndrome and relieved by fasciotomy after childbirth

Jan Roar Orlin^{1,2}, Jarle Øen³, John Roger Andersen⁴, Ivar Jostein Tjugum⁵, Hans Jacob Westbye², Jomar Roska⁶, Helene Aasved^{1,2} & Kjersti Hjelmeland⁷

¹Section of Orthopaedic Surgery, Department of Surgical Sciences, University of Bergen, Bergen, Norway

²Department of Orthopaedics, Førde Central Hospital, Førde, N-6807, Norway

³Department of Anaesthesiology, Førde Central Hospital, Førde, N-6807, Norway

⁴Department of Health studies, Sogn and Fjordane University College, Førde, N-6803, Norway

⁵Department of Gynaecology and Obstetrics, Førde Central Hospital, Førde, N-6807, Norway

⁶Department of Physical Medicine and Rehabilitation, Førde Central Hospital, Førde, N-6807, Norway

⁷Department of Neurology, Førde Central Hospital, Førde, N-6807, Norway

Correspondence

Jan Roar Orlin, Tårnveien 26, Ås N-1430, Norway. Tel: +47-91191750 (mobile); Fax: +47-57722501; E-mail: ja-or@online.no

Funding Information

No funding information provided.

Received: 27 September 2013; Revised: 9 January 2014; Accepted: 20 February 2014

Clinical Case Reports 2014; 2(3): 103–107

doi: 10.1002/ccr3.73

Key Clinical Message

A case of intolerable leg pain in pregnancy, caused by Chronic Compartment Syndrome (CCS), is presented. Increasing amounts of opioids were given throughout the pregnancy. Anesthetical dilemmas and surgery are discussed. In conclusion, early surgery rather than opioids is recommended.

Keywords

Anesthetics, chronic compartment syndrome, fasciotomy, leg pain, pregnancy.

Introduction

In spite of numerous reports on leg cramps during pregnancy which usually cease after birth, an explanation to its cause or a scientifically based treatment for extreme cases has yet to be offered. In a postpartum study based on the return of a questionnaire from 78/120 women, 45% had experienced leg cramps and mostly after the 25th week of pregnancy [1]. Cramps occurred mostly at night about twice a week, resulting in loss of sleep, reduced well-being, and work capacity. Patients were not questioned about possible leg cramps prior to the pregnancy.

Since the monography by Renemann in 1968, Chronic Compartment Syndrome (CCS) of the legs has been associated with soldiers and sportsmen only [2]. Diagnostic standards and the extent of surgery have been discussed. Recently a diagnostic protocol was published in which decision to operate CCS can be based upon clinical findings alone [3]. This case report was part of that prospective material.

Case Report

A 33-year-old woman with Attention Deficit/Hyperactivity Disorder, pregnant for the fifth time, had been treated for hypothyroidism until 2005 where after treatment seemed unnecessary. She had also been operated for bilateral carpal tunnel syndrome with satisfactory result in 2003. Prior to her fifth pregnancy, she had for many years suffered from leg pain which deteriorated at physical activity. Due to that pain she had been unable to tend to her café-job for the last 2 years. In the presence of disturbing leg cramps occurring days and nights, a diagnostic pathway for CCS was followed: The patient was seen by a neurologist, a specialist of physical medicine and rehabilitation and an orthopedic surgeon. Magnetic resonance imaging (MRI) of the spinal canal and laboratory tests were performed together with the vascular status, pain drawing, a Visual Analogue Scale (VAS) pain score, and a health-related quality of life survey.

Examination by a neurologist had eliminated common neuropathies. Neurography had resulted in normal findings. A specialist of rehabilitation medicine (coauthor) had

suggested CCS of the legs as cause of her pain. He noted that her leg pain had aggravated with menses and that a component of lumbar pain increased concomitantly. She was therefore remitted to orthopedic examination and was seen by the first author on 30 August 2007. Her expected termination was 23 March 2008. Her body weight was 68 kg and her height 168 cm. She stated that her leg pain, persistent for years, was similar to toothache and pinpricks, increasing to pressure and cramps with walking gradually more limited distances. She was now unable to sleep continuously more than 3 h before having to get out of bed and walk to overcome leg cramps. The first toe would always cramp into dorsiflexion, and although both her legs were painful, the right leg was worse than the left. She made a pain drawing (Fig. 1) and a VAS pain score, commenting spontaneously that 120% pain was more like hers (a patient with less than 50% VAS pain score is usually not in need of surgery). Upon palpation of her legs, tenderness seemed excessive in all muscle compartments, perhaps maximal in the lateral compartments, increasing in all during an exertional step test [3]. Arterial pulse was normal both in the groins, in the ankles, and in the feet. There were no signs of venous insufficiency.

A lumbar computed tomography and MRI showed completely normal findings. On examination of peripheral nerves in the legs, both before and after a step test, skin sensitivity was found to be reduced bilaterally in the areas of the nervus fibularis profundus, the nervus fibularis superficialis, and the nervus suralis while normal sensitivity was found in the dermatomes above knee level. Her

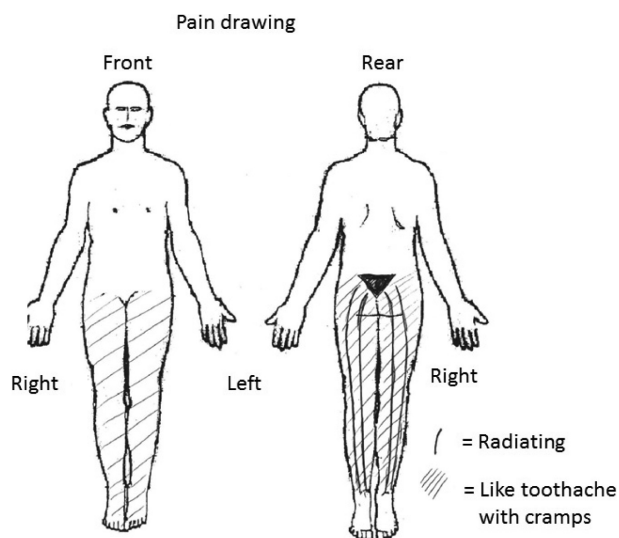


Figure 1. Preoperative pain drawing. The lines represent radiating pain, drawn very differently from sciatic pain. The cross-hatched area represents “toothache-like” pain. The pain located above the knees might be considered as referred pain because it no longer existed postoperatively.

tentative diagnosis was bilateral CCS. Pressure measurements were postponed because they frequently led to increased pain for days.

The decision on when to perform surgery was left to the obstetricians. The attitude of the orthopedic department was one of expectancy: surgery could wait until the end of the first trimester or midway through the pregnancy as a caution toward unwanted medicament effects. The patient stated that she did not want to go through with this pregnancy if she could not be relieved of her enormous leg pain. Because the therapy in question was unfamiliar, another hospital was asked for advice. The recommendation became one of wait and see. Instead, her general practitioner had to give her increasingly high doses of morphine, but with hardly any effect on her leg pains. Nor did she experience any effect from other tablets which were discontinued quickly. In detail, morphine in doses of 10 mg six times in 24 h was given in August 2007 with hardly any effect. From September 2007 until February 2008 she was treated with Norspan plaster 5 μ g per hour, which was changed every week. During the same period she was given meperidine supp. 100 mg at night to get 2–3 h of sleep. On 28 February 2008, the date of decision to do an earlier Caesarian section, an additional dose of 15 mg morphine had no effect.

In view of her intractable pain, a Caesarian section was planned for 10th March 2008, but the date was expedited due to her pain which was unrelieved even by epidural anesthesia. The Caesarian section was performed with spinal anesthesia on 23 February 2008. The spinal anesthesia did not either have the expected effect on her pain, and finally inhalation and intravenous medicaments were added. She then gave birth to a boy with body weight 2880 g and Apgar scores 9–10–10.

As morphine dose reduction started, she received support from an anesthesiologist and a psychiatrist. She did not admit to any leg pain reduction after birth, but she agreed to go home to rest and gather strength before surgery. She entered the hospital on 22 April 2008 when pressure measuring was performed (Table 1). After the step test only one compartmental pressure was measured above 30 mmHg, but tenderness at palpation and skin sensitivity reduction in the forefoot indicated the need for fasciotomy in all four compartments [3]. The next day, under general anesthesia, that surgical procedure was performed in the right leg. That very evening the pain had disappeared in her right leg and the referred lumbar pain in the right side was markedly reduced. After three more months the VAS pain score in the right leg was down to 30% and she wanted and received identical surgery in her left leg on 30 July 2008. Postoperatively she again experienced immediate pain relief.

Table 1. The intramuscular pressures measured before and after an exertional step test for 3 min. Previous “golden standard” for diagnosis of CCS has been measured pressures above 30 mmHg.

Compartment measured	Pressure before step test (mmHg)	Pressure after step test (mmHg)
Left anterior	30	16
Left lateral	13	22
Left posterior (superficial)	8	13
Right anterior	26	36
Right lateral	9	27
Right posterior (superficial)	12	12

At follow-up after 2 years her legs were pain-free and the VAS pain score in both had been reduced from 100% to 0% that is the best score possible. Furthermore, all her lumbar pain had disappeared. Consequently, her quality of life had improved in many ways. She was able to walk, run or dance unlimited, she could sleep undisturbed by pain at nights, and she had begun to improve her social situation, blaming all her problems on the previous leg pains. A health-related quality of life survey (HRQL), SF-8 [4], providing information on physical, mental, and social dimensions of health, was markedly below normal scores before the operation, indicating severe impairments in HRQL, while after the operation the score was normalized and even exceeded normal scores for women aged 35–39 years (Table 2). At the 5 years follow-up the situation was unchanged.

Discussion

A 33-year-old woman was so disturbed by leg pain with cramps, lack of sleep, and tiredness that she wanted to terminate her fifth pregnancy unless she could be relieved of her pains. Because CCS of the legs previously has not been reported as a cause of leg cramps, traditional relentlessness toward general anesthesia in the first trimester

Table 2. The patient’s SF-8 scores (average) before and after surgery and population norm scores for women aged 35–39 years (average \pm SD).

SF-8 domains	Before surgery	After surgery	Population norm ($n = 488$)
Physical functioning	21.5	54.0	48.6 \pm 7.3
Role physical	23.0	54.0	48.4 \pm 7.7
Bodily pain	25.4	60.8	49.4 \pm 8.7
General health	22.8	59.5	49.0 \pm 7.5
Vitality	28.1	61.8	48.4 \pm 7.8
Social functioning	23.4	49.5	47.4 \pm 8.5
Role emotional	21.7	45.7	46.2 \pm 7.4
Mental health	21.4	56.8	46.8 \pm 9.7

forced this patient to endure intractable pain until after she had given birth. A literature search revealed that modern anesthetics no longer represent much of a risk to the fetus (see below). Thus, a surgical solution could have been offered to this patient as soon as the diagnosis was obvious.

Anesthetical considerations concerning fasciotomy during pregnancy

The risks associated with general anesthesia are increased during pregnancy. Airway management can be impaired due to upper airway edema and vascular changes caused by the hormonal state [5]. Studies have shown a 3.3% risk for difficult intubation and 0.4% risk for failed intubation during pregnancy. This is an eightfold increase compared to non-pregnant women [6]. There is also an increased risk for esophageal regurgitation and aspiration due to decreased esophageal sphincter tonus during pregnancy combined with difficult manageable airways. In addition, the time to desaturate is decreased in the pregnant patient due to increased oxygen consumption and a decreased functional residual capacity [7]. Van de Welde et al. reviewed anesthesia to the pregnant patient and concluded that the drugs used today in general anesthesia are not considered to be teratogenic [8]. There are, however, several studies that link surgery during pregnancy with increased rate of spontaneous abortions, low-birth-weight and death within 168 h of live born infants. The anesthetic drugs used have shown to have minimal effect on uterine blood flow [9, 10]. The risks of hypovolemia and hypoxemia for the fetus are increased, however, due to the systematic hemodynamic effects such as vasodilatation and cardiac depression in the mother.

There is less risk associated with regional anesthesia during pregnancy than with general anesthesia. One study found the risk associated with general anesthesia during pregnancy to be a 17-fold increase in complications when compared to regional anesthesia [5]. The main concerns when performing surgery in regional anesthesia are hypotension and local anesthetic toxicity or anaphylaxis. The procedure can be handled in the same way as a Caesarian section in regional anesthesia. Precautions should be undertaken, and appropriate vasopressors must be ready, to be prepared for hypotension and anaphylaxis as a result of injection of local anesthetics. It is recommended to perform the surgery in the second trimester and elective surgery should be avoided.

The reported patient was given opioids (morphine) for pain relief during the pregnancy. The Norwegian drug information catalogue lists long-lasting morphine use during pregnancy as a possible agent for neonatal absti-

nence syndrome with symptoms as cramps, irritability, vomiting, and increased mortality. The FDA-approved box-labeling according to UptoDate lists morphine as a class C drug (“Risks cannot be ruled out”) during pregnancy. According to the warning, morphine has not shown teratogenic effects in animal studies, but reduced growth and behavior abnormalities in offspring have been observed. The frequency of congenital malformations has not been reported to be greater than expected in children from mothers treated with morphine during pregnancy. The recommendation is to use minimal, if any, opioids during pregnancy in patients with chronic non cancer pain. The risk of analgesics for pain during pregnancy must be weighed against the risks associated with surgery during pregnancy. The reported patient experienced slight or no relief from increasing doses of morphine. One may, therefore, discuss if the optimal analgesic regime was identified. She did not receive nonpharmacological treatment as iron replacement, mental training, leg stretching or elastic stockings.

Diagnostic considerations

At this young age, the presence of differential diagnoses like arteriosclerosis and venous insufficiency may be excluded by clinical examination only. Unspecific neuritis, polyneuritis, diabetic neuropathy, and spinal lesions must be excluded as well. It might appear a paradox

that normal results from electrophysiological examination are reported while changes of sensitivity are found. This calls for some explanation. Pain as an isolated symptom, will usually only affect small and unmyelinated nerve fibers (small fibers). Small fibers are not available for measurements by electromyogram/nerve conduction study. When the sense of touch is diminished, as is the case with our patient, you would expect an effect on myelinated fibers (A-alpha). This would lead to reduced nerve conduction. The challenge is that a wide range of normal values for the standard parameter of nerve conduction exists. Thus, electrophysiological examination has a low sensitivity in demonstrating pathological findings. Our patient had symptoms from both lower extremities, if not we could have increased the sensitivity by comparing to the healthy side.

Pain drawing has proven of value in discriminating a radicular pain caused by the L5-or S1-nerve roots from leg pain caused by CCS and possibly its referred pain to the trochanter and lumbar region, sometimes even up to the scapula. A closer look at this patient’s pain drawing (Fig. 1) shows that its character is by far exceeding the radicular pattern usually seen in sciatica. Clinically, one needs to discriminate the pain in the anterior part of the leg caused by irritation of a L5-nerve root from the pain caused by an anterior CCS and correspondingly by the other compartments. Recently clinical examination proved more adequate

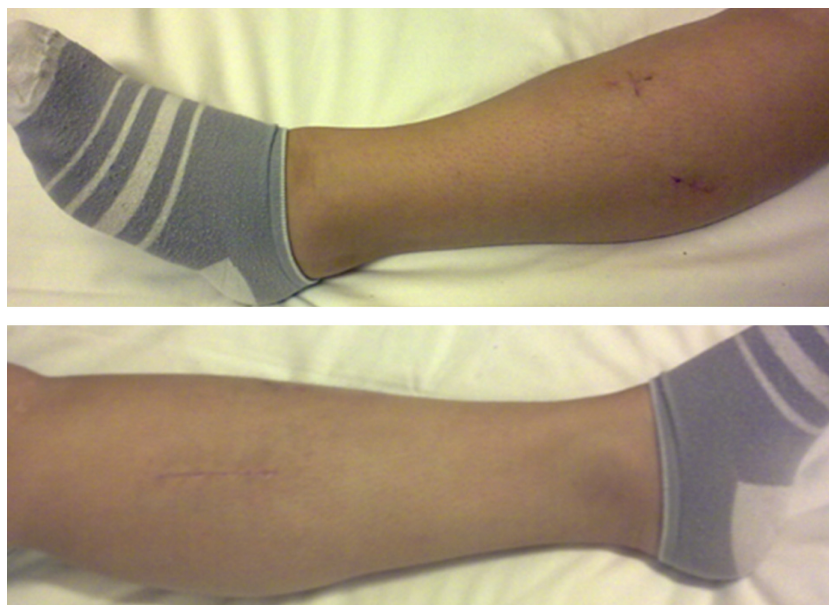

Figure 2. Photo of patient’s legs. During surgery, symmetrical skin incisions were performed in the right and left legs. On the left leg, the three scars have been colored for better visualization. The fascias were split by distances of ~20 cm in the anterior, lateral and superficial posterior compartments, whereas the fascias of the deep posterior compartments were split by distances of ~10 cm.

than pressure measurement in deciding how many compartments need fasciotomy in order to achieve permanent pain free legs [3]. The technique of fasciotomy of all four leg compartments, paralleling the general recommendation in acute cases, was adapted toward modern endoscopic principles in order to evade disturbing scars whilst trying not to damage local nerves (Fig. 2). In the same study, CCS was associated with leg cramps in 86.5% of patients and hormonal disturbances occurred in 30%. This seems to call for the attention of specialists in internal medicine. Possibly CCS and other peripheral nerve entrapments might be caused by edema from some systemic disease.

In conclusion, a diagnosis of CCS should be anticipated if (1) leg pain or cramps are caused both by walking and running, leading to awakening at night, (2) radiological findings are normal and (3) neurological changes are limited to numbness or reduced sensitivity in the forefoot areas of the *nervus fibularis profundus*, the *nervus fibularis superficialis*, and/or the *nervus suralis*. The risks for the fetus from high-dose opioid treatment remains unclear, but negative effects cannot be ruled out. If no treatment is adequate to ensure a bearable pain situation for the patient during the pregnancy, surgery can be considered. But only after careful consideration of the risks associated and thorough information and consent of the patient. The anesthesia of choice in this patient would be neuraxial block. This patient clearly expressed that she would have preferred the surgical procedure early in the pregnancy rather than post partum.

Conflict of Interest

The authors report no conflicts of interest. The authors alone are responsible for the content and writing of the paper.

References

1. Valbø, A., and T. Bøhmer. 1999. Leggkramper i svangerskapet – hvor hyppig forekommer det? (Leg cramps in pregnancy – how frequent is it?). *Tidsskr. Nor. Laegeforen.* 119:1589–1590.
2. Renemann, R. S. 1968. The anterior and the lateral compartment syndromes of the leg. Mouton, The Hague-Paris.
3. Orlin, J. R., J. Øen, and J. R. Andersen. 2013. Changes in leg pain after bilateral fasciotomy to treat chronic compartment syndrome: a case series study. *J. Orthop. Surg. Res.* 8:6.
4. Ware, J. E., M. Kosinski, J. E. Dewey, and B. Gandek. 2001. How to score and interpret single-item health status measures: a manual for users of the SF-8 Health Survey. QualityMetric, Inc., Lincoln.
5. Lynch, J., and S. Scholz. 2005. Anaesthetic-related complications of caesarean section. *Zentralbl. Gynecol.* 127:91–95.
6. Samsoon, G. L., and J. R. Young. 1987. Difficult tracheal intubation: a retrospective study. *Anaesthesia* 42:487–490.
7. Conklin, K. A. 1991. Maternal physiological adaptations during gestation, labor and the puerperium. *Semin. Anesth.* 10:221.
8. Van De Velde, M., and F. De Buck. 2007. Anesthesia for non-obstetric surgery in the pregnant patient. *Minerva Anesthesiol.* 73:235–240.
9. Alon, E., R. H. Ball, M. H. Gillie, J. T. Parer, M. A. Rosen, and S. M. Shnider. 1993. Effects of propofol and thiopental on maternal and fetal cardiovascular and acid-base variables in the pregnant ewe. *Anesthesiology* 78:562–576.
10. Okutomi, T., R. A. Whittington, D. J. Stein, and H. O. Morishima. 2009. Comparison of the effects of sevoflurane and isoflurane anesthesia on the maternal-fetal unit in sheep. *J. Anesth.* 23:392–398.